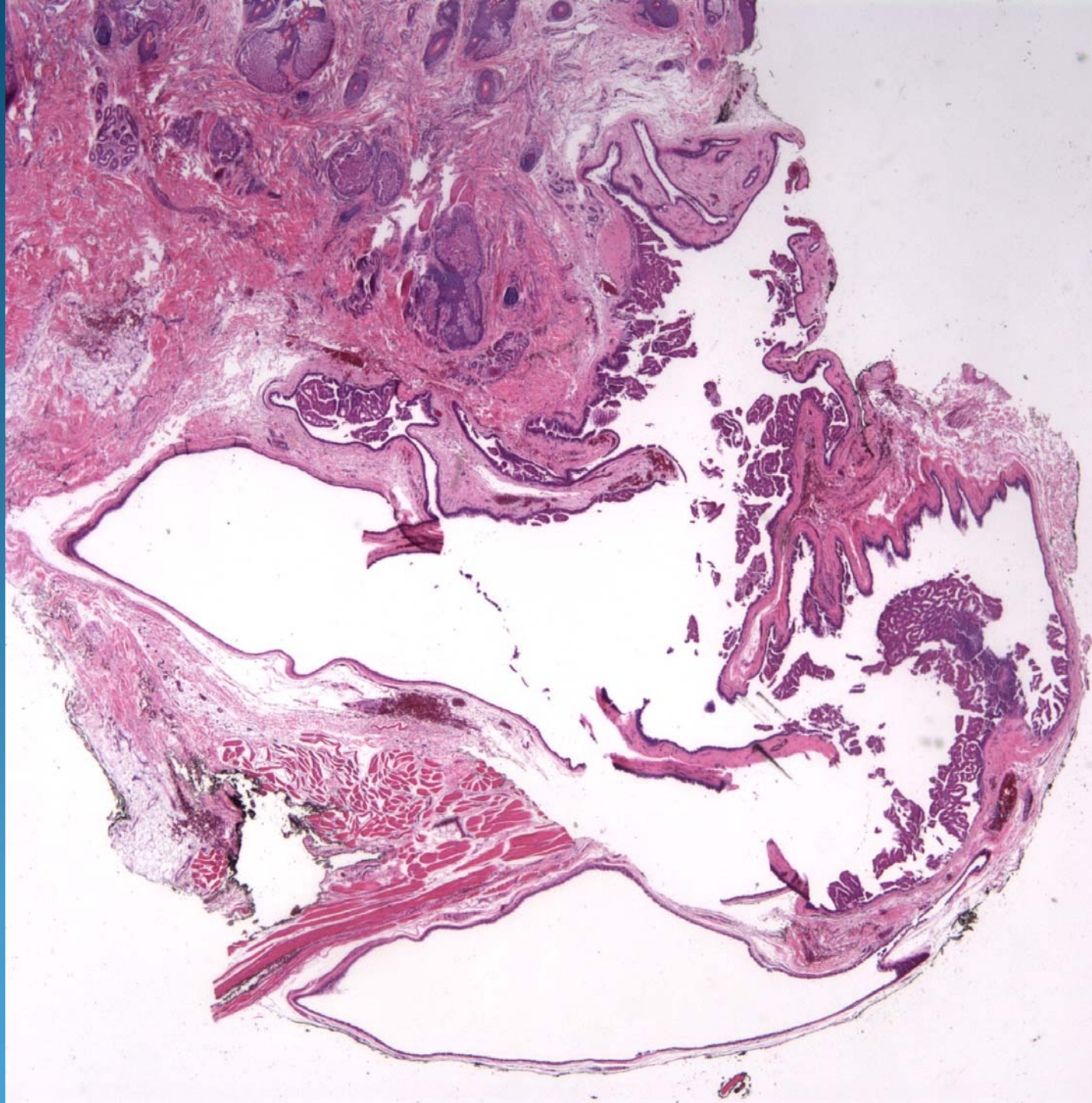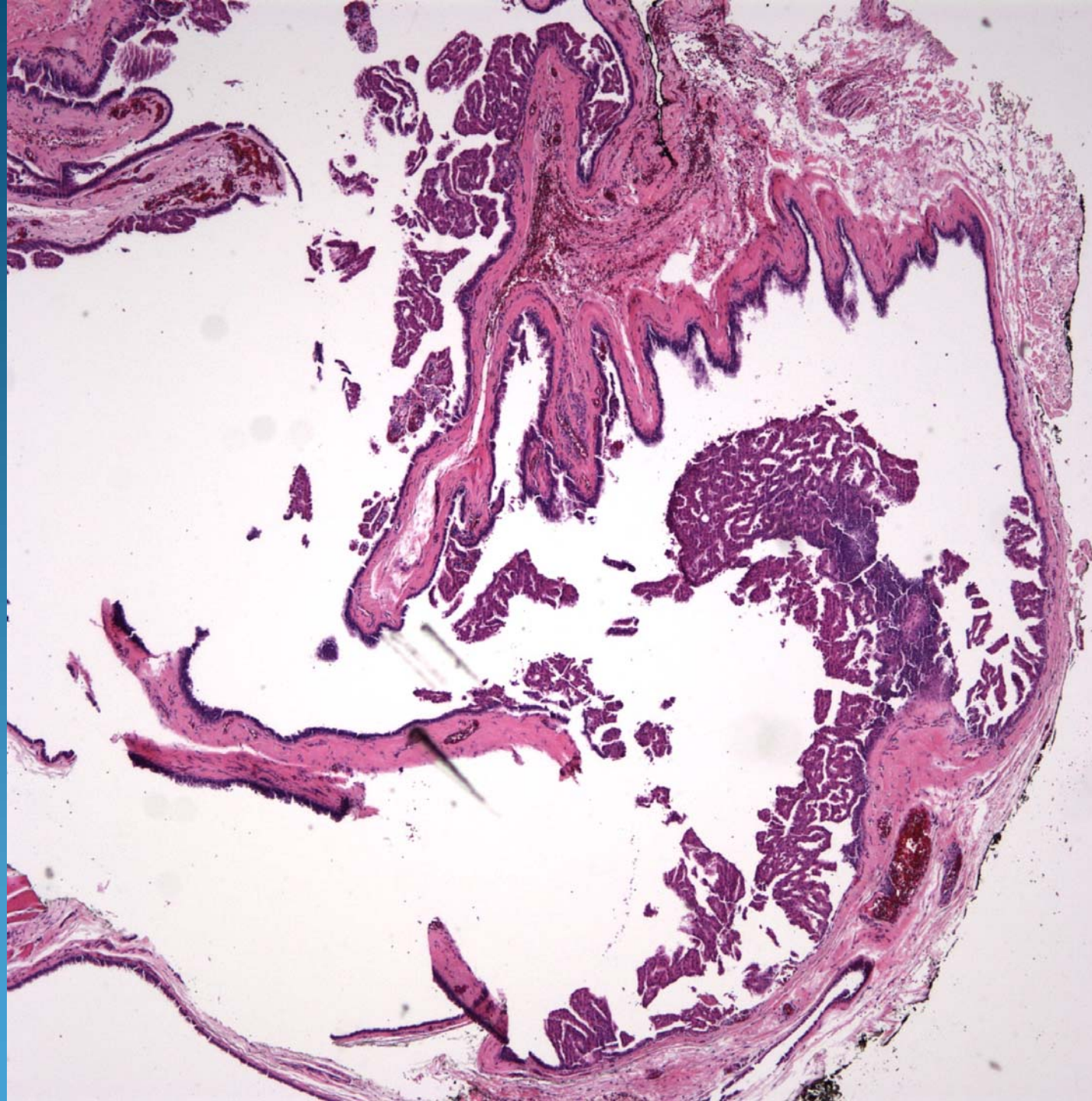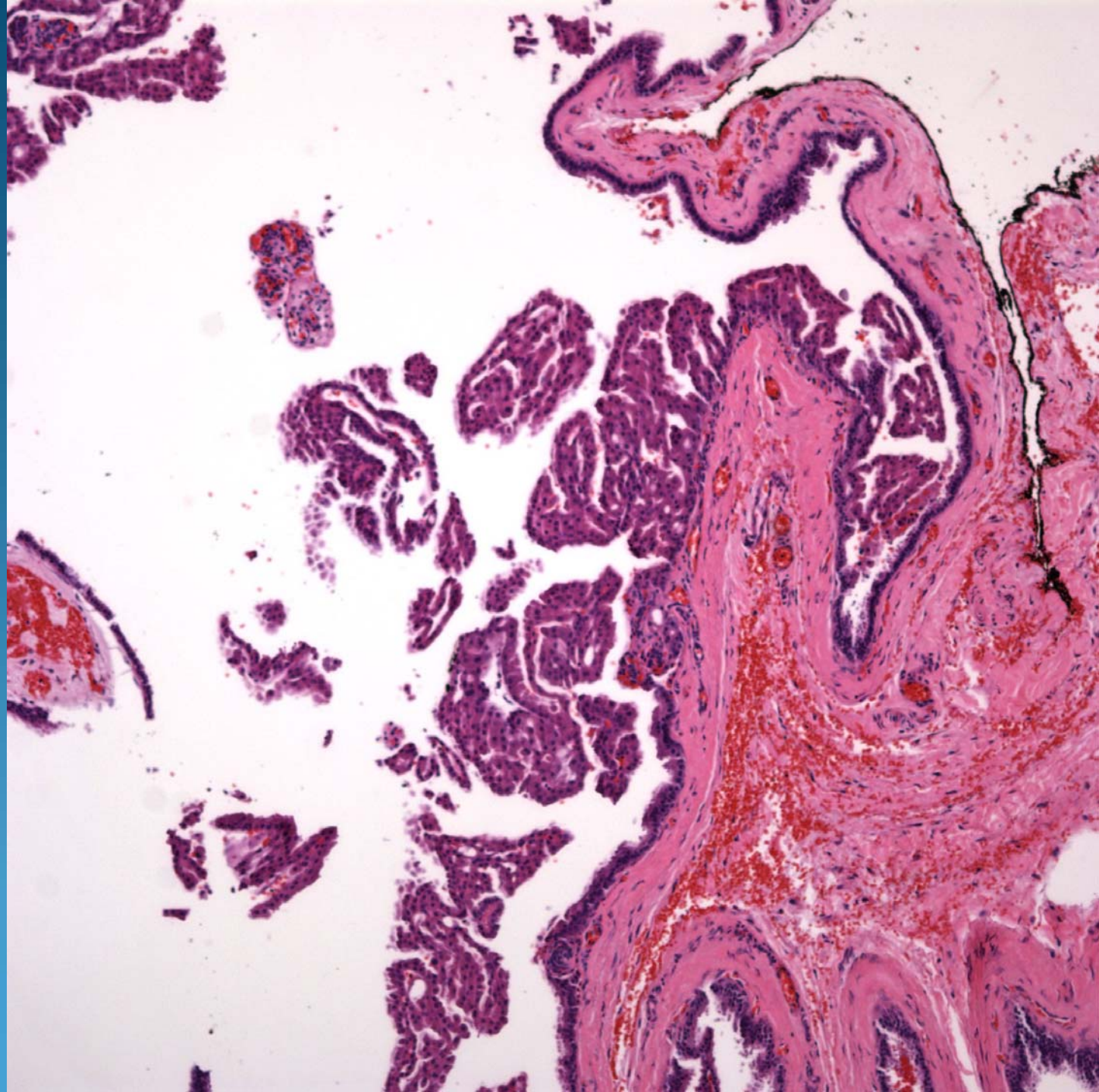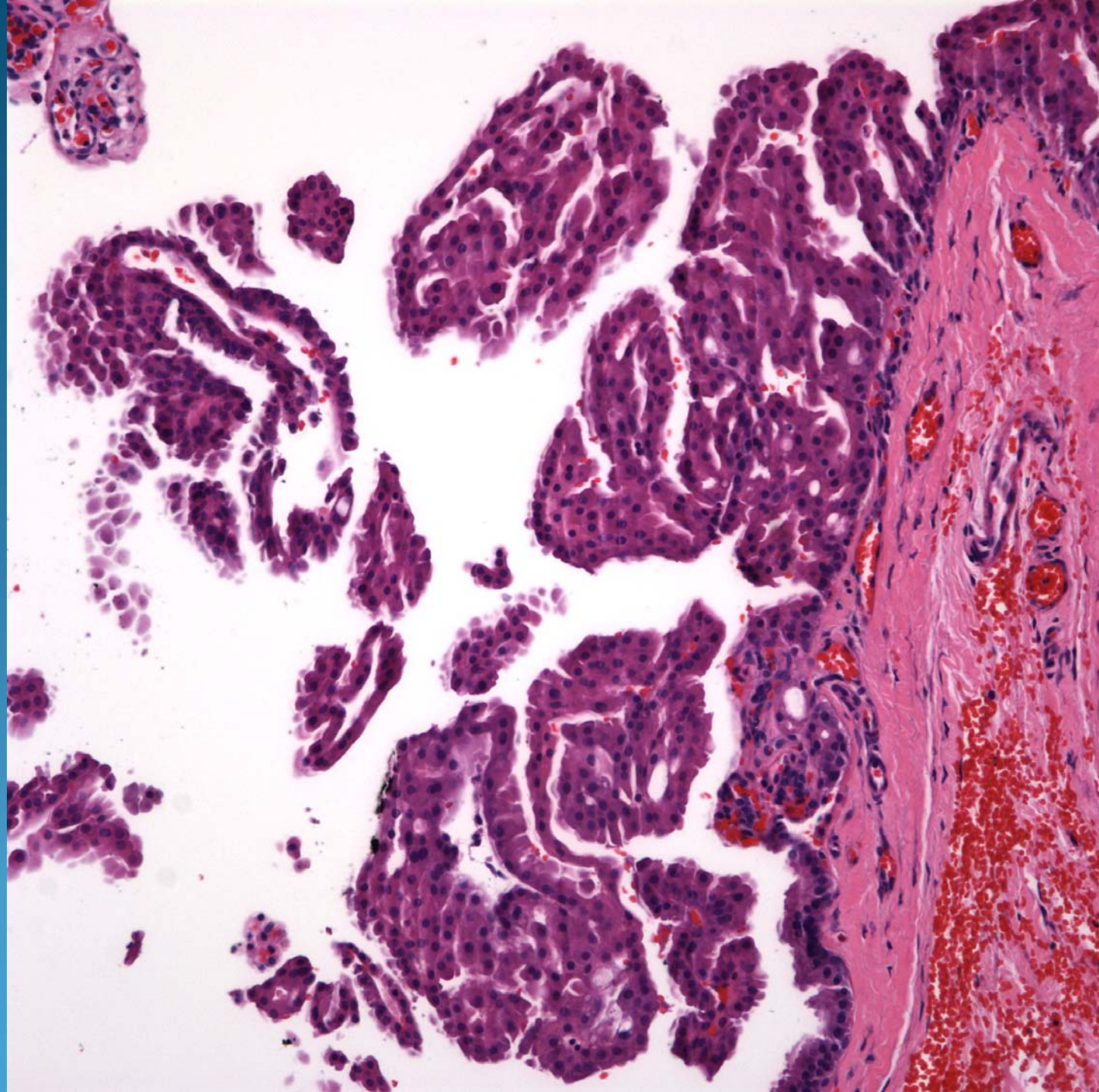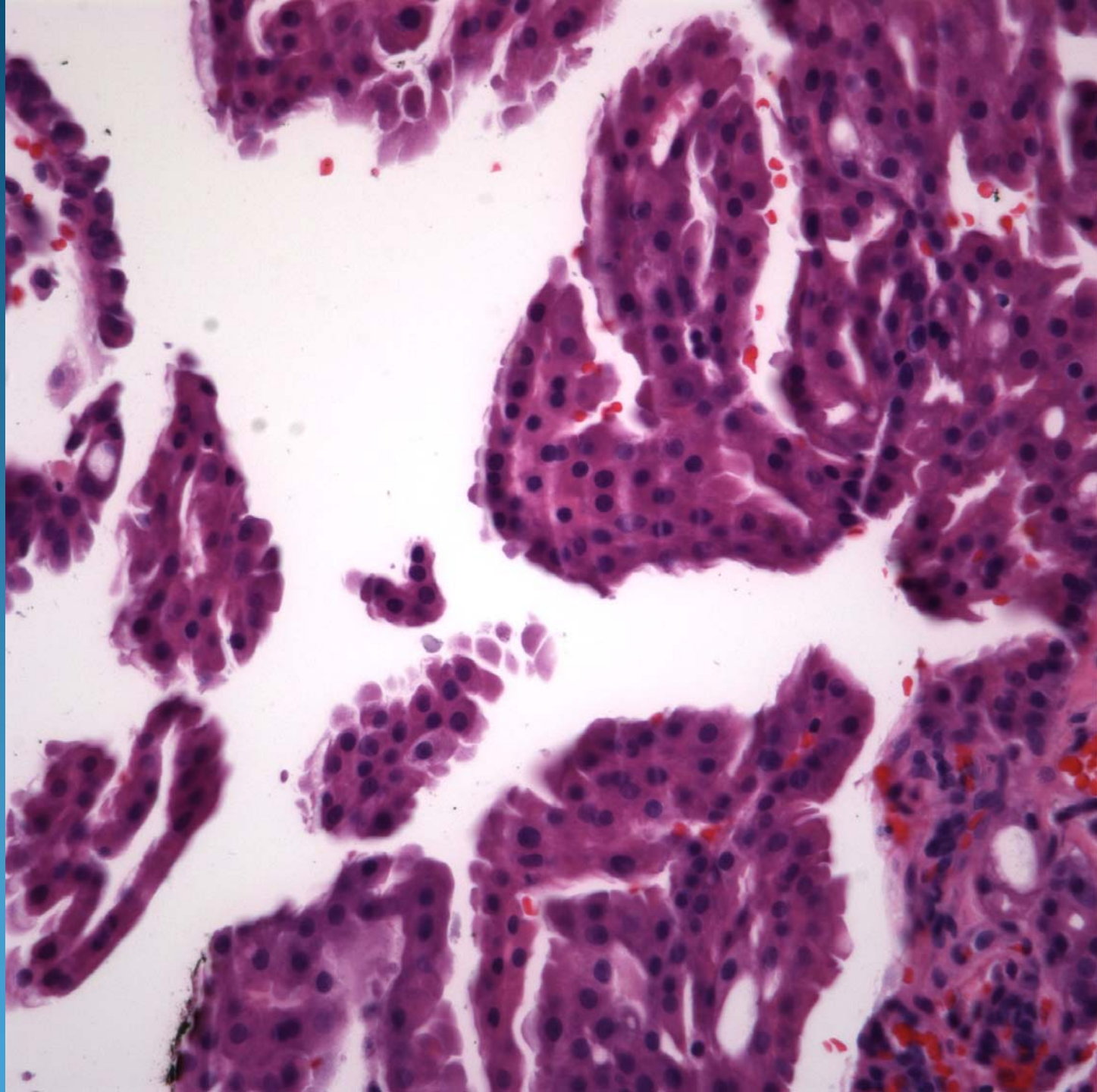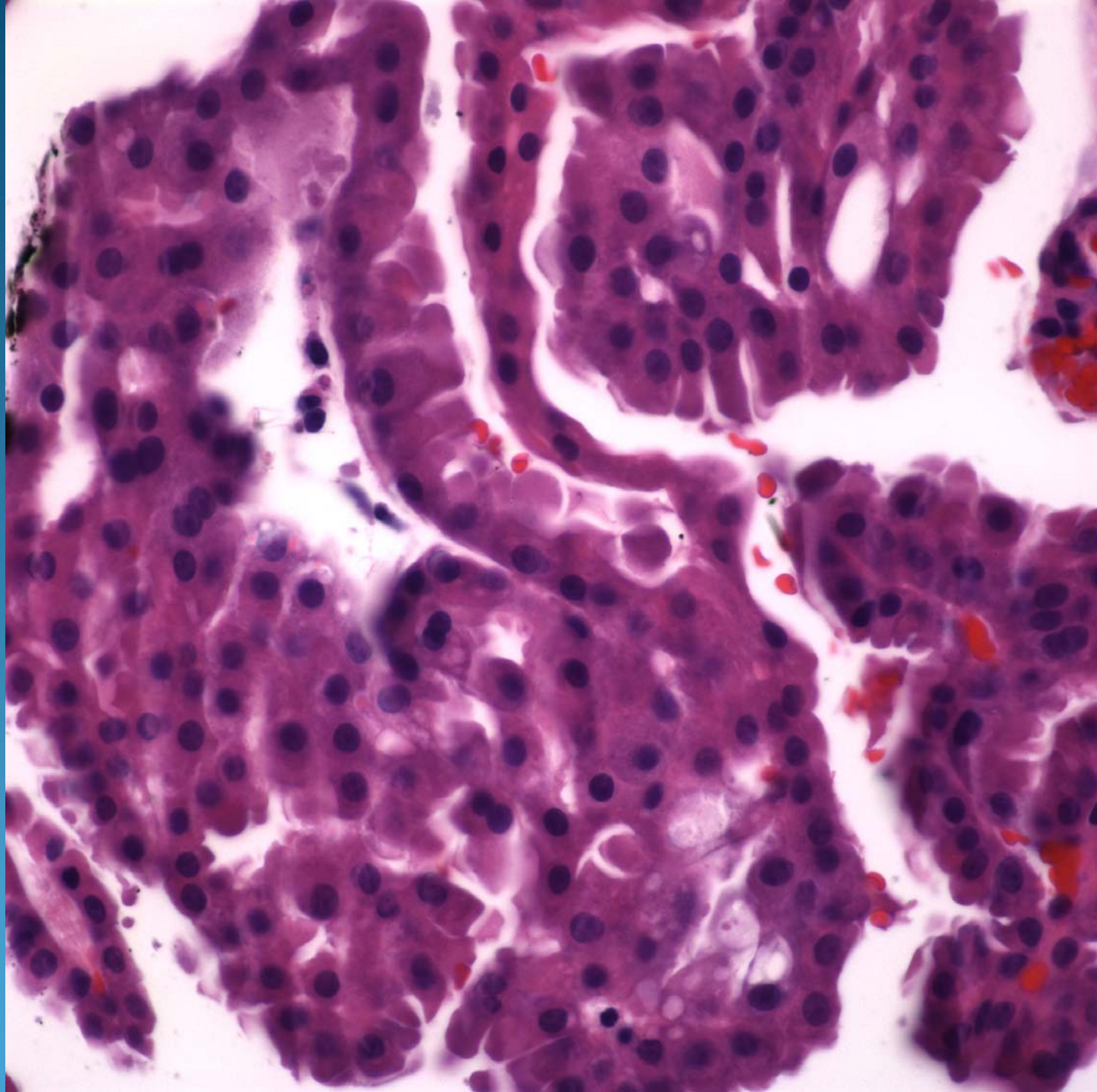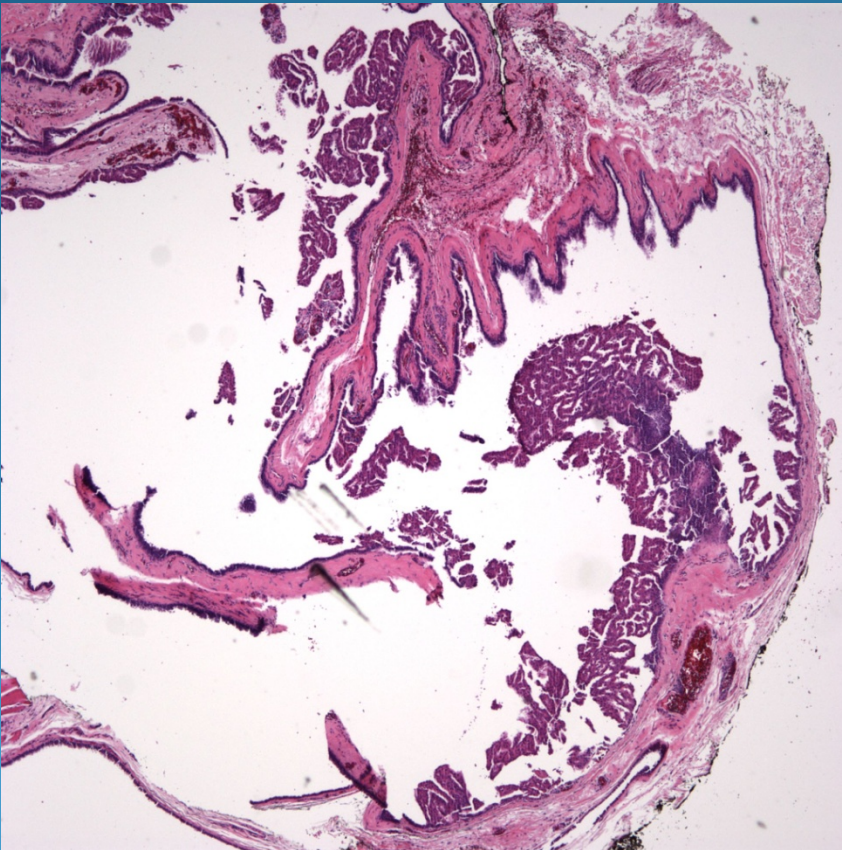


Apocrine Cystadenoma

Pearls



- Circumscribed cyst lined by apocrine epithelium
- Apocrine snouting
- May have multiple epithelial layers with papillary and cribriform projections
- Minimal cytologic atypia